

CORRESPONDENCE

Using Imaging for Education and Clinical Excellence

To the Editor

The *Optometry and Vision Science* Guest Editor team, led by Scott Read, as well as all of the authors, has produced a remarkable 300-page feature issue on ocular imaging in *Optometry and Vision Science*. As you note in your editorial to

the issue, the advances in ocular imaging are truly revolutionary.¹

Although Read et al.² mention numerous advantages with ocular imaging, one advantage that I believe deserves greater attention is the benefit to education and clinical excellence. Because optical coherence tomography (OCT) allows comparison between clinical appearance and structure, there are potential broad benefits in educa-

tion for both the anterior and posterior ocular structures.

It is remarkable that OCT so clearly shows the neural retina and nerve fiber layers, although these layers are relatively transparent to light in the visible range.³ Kremser et al.⁴ deftly described the translucency of the retina, calling it “a delicate diaphanous tissue.” Quigley⁵ commented on the difficulty of seeing the retinal nerve

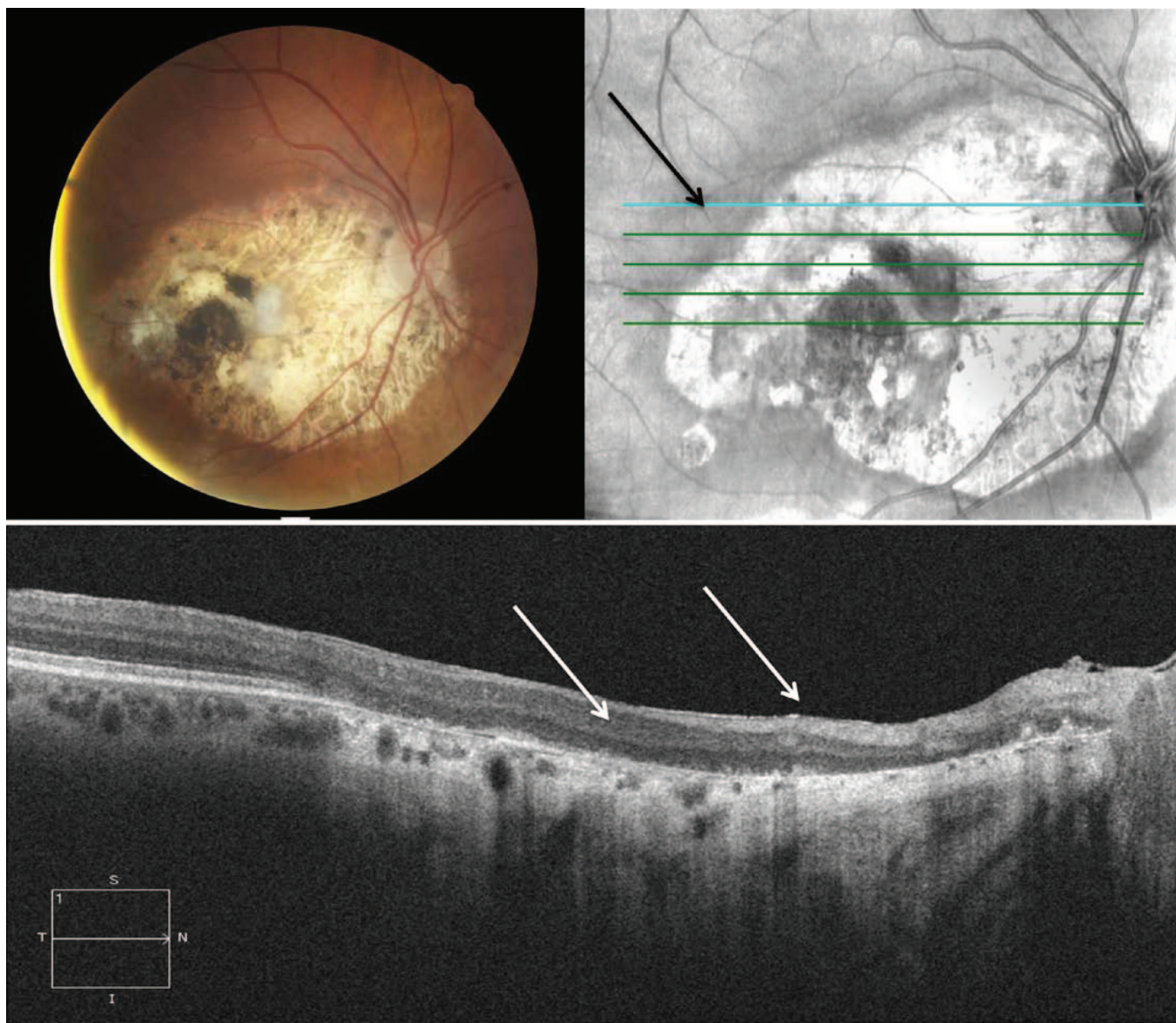


FIGURE 1.

Seeing the invisible retina. Presumed ocular toxoplasmosis scar in standard digital fundus camera image (upper left panel), posterior-segment OCT raster scan (upper right panel), with location shown in inset (below). The atrophic retina (left arrow) and nerve fiber layer (right arrow) are shown clearly in the OCT image, but are difficult to see against the white sclera in the fundus photo.

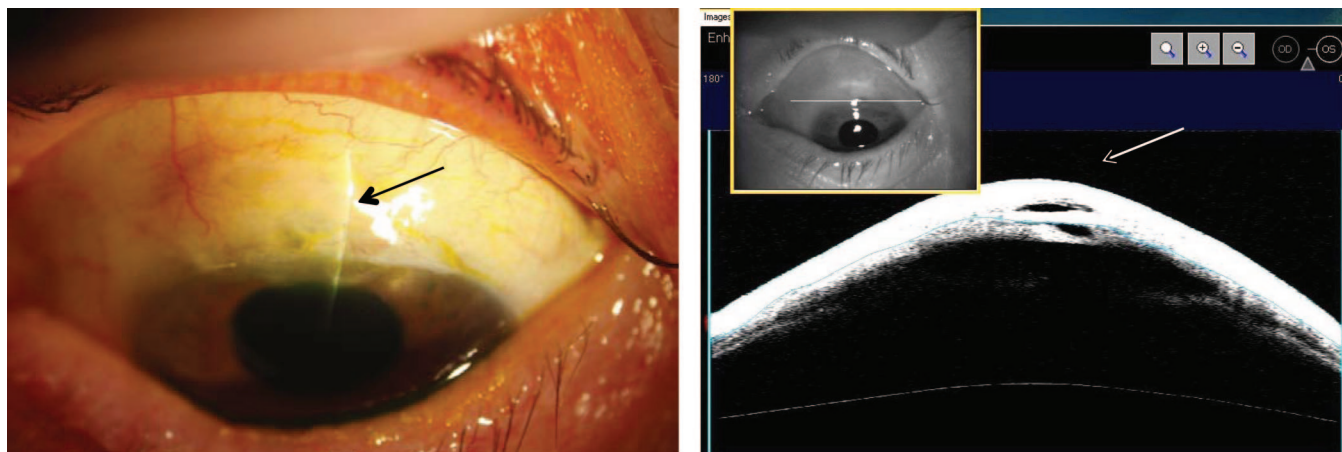


FIGURE 2.

Left panel: seeing inside the sclera. Right panel: white-light image of a filtering bleb (trabeculectomy) and anterior-segment OCT horizontal section, in the same patient, showing the deeper structures associated with the filtering bleb.

fiber layer using color photographs taken in white light, and that even in green (red free) light, the presence of cataract or smaller pupils could make observations difficult.

In University education programs, it takes time for students to gain an understanding and appreciation of the appearance of the relatively transparent neural retinal layers and the often-concealed choroid. Using the (nearly) invisible light of OCT to observe the (nearly) invisible ocular structures, this educational process can now be greatly facilitated and taught at a higher level. The clinical appearance of the various ocular fundus layers can now be readily compared with the *in vivo* histological structure via the OCT.

An interesting example is shown in Fig. 1. The patient's fundus has an extensive scar, subsequent to presumed ocular toxoplasmosis. In white-light imaging, the sclera is the main tissue visible in the scar area, and the neural retina is difficult to see. However, the OCT scan clearly shows the atrophic retina and the nerve fiber layer overlying the sclera.

The converse example is in Fig. 2. Here the anterior-segment OCT wavelengths allow imaging of the deeper structures associated with a filtering bleb. These channels are invisible when the sclera is viewed with white light. An analogous methodology with posterior-segment OCT is using specific infrared wavelengths that penetrate the retinal pigment epithelium to image the choroid and sclera.⁶

A further benefit with ocular imaging relates to clinical education in ocular disease. With more than 150 disease condi-

tions that may affect the posterior eye alone,⁷ it can be of significant assistance for students to be able to see the affected tissue structures via OCT for different clinical disease conditions.

There is potential for even experienced eye care practitioners to use OCT measurements to validate or enhance their skills, particularly with quantitative clinical techniques. Quantitative optic nerve assessments include estimation of the cup-disc ratio and the optic nerve head diameter and assessment of integrity of the neuroretinal rim. Quantitative anterior assessments include the Van-Herrick ratio and central anterior chamber depth. All these clinical estimations may be verified or compared with the corresponding OCT measures. In this way, student or practitioner experience with imaging may enable enhancement of standard clinical evaluations.

**Adrian S. Bruce, BScOptom, PhD,
FAAO**

*Australian College of Optometry and
Department of Optometry and Vision Sciences
The University of Melbourne
Melbourne, Victoria
Australia*

REFERENCES

1. Adams AJ. Feast your eyes on the image. *Optom Vis Sci* 2012;89:519–20.
2. Read SA, Williams DR, Wojtkowski M, Roroda A, Nichols JJ, Mutti DO, Kaufman PL, Carney LG. Imaging and measurement in the eye: now and ahead. *Optom Vis Sci* 2012;89:521–3.
3. Folio LS, Wollstein G, Schuman JS. Optical coherence tomography: future trends for imaging in glaucoma. *Optom Vis Sci* 2012;89:554–62.

4. Kremser B, Troger J, Baltaci M, Kralinger M, Kieselbach GF. Retinal thickness analysis in subjects with different refractive conditions. *Ophthalmologica* 1999;213:376–9.
5. Quigley HA. Examination of the retinal nerve fiber layer in the recognition of early glaucoma damage. *Trans Am Ophthalmol Soc* 1986;84:920–66.
6. Torzicky T, Pircher M, Zotter S, Bonesi M, Gotzinger E, Hitzenberger CK. High-speed retinal imaging with polarization-sensitive OCT at 1040 nm. *Optom Vis Sci* 2012;89:585–92.
7. Bruce AS, O'Day J, McKay D, Swann PG. *Posterior Eye Disease and Glaucoma A-Z*. Oxford, United Kingdom: Elsevier; 2008.

Author's Response

We thank Dr Bruce for his positive comments regarding the May 2012 feature issue of *Optometry and Vision Science* on "Imaging and Measurement in the Eye." We agree that many of the advances in ocular imaging presented in the feature issue do have the potential to also benefit education and promote clinical excellence. Ocular imaging techniques such as optical coherence tomography as illustrated in the examples in Dr Bruce's letter, and other techniques highlighted in the feature issue, such as adaptive optics or autofluorescence retinal imaging, have the potential to provide both important new insights regarding the detailed structural and functional characteristics of normal ocular tissues and also the changes in these tissues associated with diseases and surgical procedures beyond that provided by traditional clinical examination techniques. The new insights